

Neurological Disorders Complicating Pregnancy - Focus on Obstetric Outcome

SANDYA RENUKESH¹, LAVANYA RAI²

ABSTRACT

Introduction: Neurological disorders in pregnancy can be pregnancy related or can be caused by exacerbation of a pre-existing neurological condition or sometimes may even be detected for the first time during pregnancy in which it might be an incidental finding. The diagnosis and management of the neurological disorders in pregnancy is always a challenging task due to varied symptomatology and risks to the fetus. The evaluation and management should be performed in a stepwise fashion and requires multidisciplinary approach.

Aim: The present study was conducted with the aim to study the influence of neurological disorders on outcome of pregnancy.

Material and Methods: This was a prospective observational study conducted over a period of 1 year (2013-2014) including 54 pregnant women with neurological manifestations. The spectrum of neurological manifestations was divided into-pregnancy specific, incidental and pre-existing neurological disorders for analysis. Five unusual cases with varied manifestations were studied in detail. Any pregnant woman presenting with neurological manifestation, irrespective of gestational age were included in the present study. The neurological manifestation and the obstetric outcome were analysed in the present study.

Results: There were 54 women with varied neurological manifestations, majority (74%) of them being primigravida.

Seizure was the most common (63%) manifestation. The incidence of pregnancy specific disorder (eclampsia), pre-existing disease (epilepsy) and incidental causes were 40.8%, 37% and 22.2% respectively. Of the 22 women with eclampsia, 15(68%) had seizure during antepartum period and 7(32%) in the postpartum period. Three patients out of 22 who had eclampsia had intrauterine fetal demise on arrival itself, whereas the perinatal outcome was good in the other 19 patients who had live born babies. The most common incidental cause in the present study was tubercular meningitis (44%). There was however a maternal and perinatal mortality in woman with structural malformation who had massive intra-ventricular haemorrhage, secondary to ruptured cerebral cavernoma. Here we have described in detail 5 patients with varied clinical manifestation causing diagnostic dilemma. They are spinal arterio-venous malformation, disseminated toxoplasmosis, massive intra-ventricular haemorrhage (ruptured cerebral cavernoma), tubercular meningitis with cortical venous thrombosis, suspected Bartter syndrome presenting as coma.

Conclusion: Neurological manifestation during pregnancy may not always be a primary neurological disorder, instead may be manifestation secondary to any systemic illness. Hence, a wide index of suspicion and neuroimaging aids in arriving at the diagnosis certainly improves the pregnancy outcome.

Keywords: Coma, Eclampsia, Epilepsy, Neurological manifestations, Seizure

INTRODUCTION

Neurological disorders in pregnancy can be pregnancy related or can be caused by exacerbation of a pre-existing neurological condition or sometimes may even be detected for the first time during pregnancy in which it might be an incidental finding [1]. Knowledge of a pre-existing neurological disorder helps to seek a multidisciplinary approach and usually has better pregnancy outcome as both the patient and her treating doctor are well aware of the disease status [2]. On the other hand the pregnancy outcome in cases of disorders diagnosed first time during pregnancy (incidental) may have a worst outcome on pregnancy and endanger maternal life [1,3]. Neurological manifestations may be due to disorder of nervous system or a result of other systemic illness. The diagnosis of neurological disorders during pregnancy is always a challenging task as the symptomatology may vary due to hormonal changes and exaggerated physiological responses during pregnancy [4]. The treatment of these neurological disorders in pregnancy is challenging due to the risks to the fetus. Neurological diseases are not commonly encountered in pregnancy, when it occurs can have serious implications on obstetric as well as neonatal outcome. The present study was hence undertaken to analyse the influence of neurological disorders on pregnancy outcome.

MATERIAL AND METHODS

This was a prospective observational study conducted in the Department of Obstetrics and Gynaecology (OBGYN), at tertiary center over a period of 1 year (2013-2014). Institutional ethical committee approval was obtained.

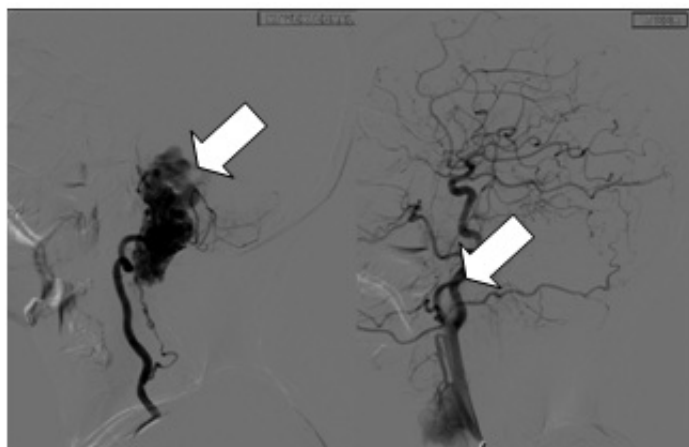
The total number of deliveries during the study period was 2730 and 1.97% (n=54) of pregnancies had neurological manifestations. Sample size was not calculated as all the 54 pregnant women who presented to us with neurological manifestations, irrespective of their period of gestation and pregnancy outcome were included in study. The spectrum of neurological manifestations was divided as pregnancy specific, incidental and pre-existing for analysis. Five unusual cases with varied manifestations as tabulated in [Table/Fig-1] were studied in detail [Table/Fig-2-5]. All women with the diagnosis of eclampsia were managed with standard regimen of magnesium sulphate. All patients with epilepsy were managed by obstetricians in consultation with neurophysicians.

Twelve women with incidental causes which included infective/inflammatory causes and a structural malformation were managed by a multidisciplinary approach. Neuroimaging was done for accurate diagnosis and management.

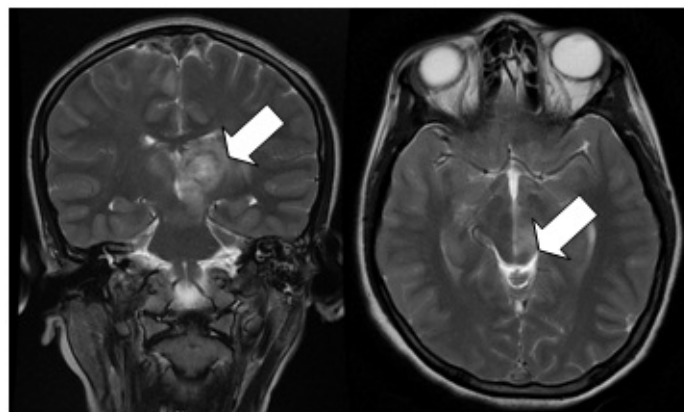
Cases	Age Parity	Complaints	Investigation	Diagnosis	Management	Outcome
Case 1	20 years Primigravida (20 weeks)	Excruciating headache Difficulty in breathing Weakness of all 4 limbs	Magnetic Resonance Angiography	Spinal arterio-venous malformation compressing on nerve roots at C2 level [Table/Fig-2].	Pregnancy termination using misoprostol Advised embolization of AVM* prior to next pregnancy	Complete recovery of quadriplegia
Case 2	20 years Primigravida (26 weeks)	Recurrent seizures x 3 days	Magnetic Resonance Imaging [Table/Fig-3]	Massive intra ventricular haemorrhage due to ruptured cerebral cavernoma	Emergency Burr hole, only transient improvement Perimortem cesarean section	Maternal mortality Neonatal mortality on 3 rd post-natal day
Case 3	26 years Primigravida (16 weeks)	Altered sensorium H/O cough with expectoration x 2 weeks	MRI [†] [Table/Fig-4] Toxoplasma Ig G, Ig M antibody assay- positive HRCT [‡] lung showed multiple nodules	Disseminated toxoplasmosis	Spontaneous abortion Tab. Sulphadiazine + Pyrimethamine for 1 month During the course of treatment she developed DIC and received massive component transfusion. Patient required ventilator support for 6 days and ICU care for total of 1 month	Recovered
Case 4	30 years Primigravida (12 weeks)	Headache Fever Altered sensorium	MRI [†] showed haemorrhagic infarcts with cerebral venous thrombosis [Table/Fig-5]. CSF ^{**} analysis suggestive of tubercular meningitis	Tubercular meningitis with cortical venous thrombosis	Manual vacuum aspiration for missed abortion Anti-tubercular treatment for 12 months Inj. Heparin for 6 weeks	Recovered
Case 5	30 years Primigravida (37 weeks)	Coma Glasgow coma scale - 3	MRI [†] - normal Serum electrolytes- severe hypokalemia (1.5 meq/l) and hypomagnesemia (1.7 meq/l)	Suspected Bartter syndrome	Delivery by cesarean section Mutation analysis declined Tab, Aldactone once daily Potassium rich diet, adequate hydration	Recovered

[Table/Fig-1]: Summary of five unusual cases.

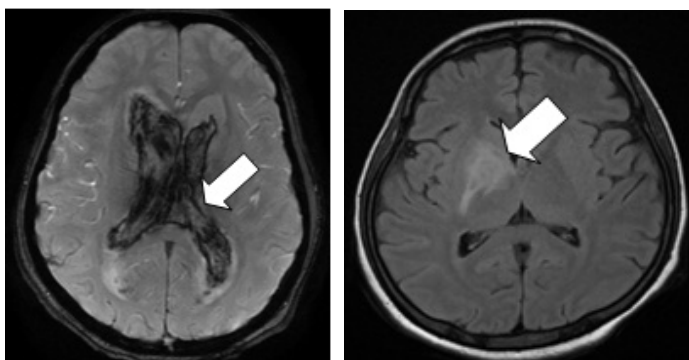
*=AVM: Arterio Venous Malformation, **CSF=Cerebrospinal Fluid, †=MRI: Magnetic Resonance Imaging, ‡=HRCT: High Resolution Computed Tomography.



[Table/Fig-2]: Angiography of Brain and spine. Shows multiple flow voids (nidus) seen in the cord at the level of C2 and cervico-medullary junction. Feeding artery arising from the anterior spinal and the right vertebral artery.



[Table/Fig-5]: MRI Brain. Shows cerebral dural venous sinus and cortical venous thrombosis with multiple venous thrombosis with multiple venous haemorrhagic infarcts.



[Table/Fig-3]: MRI Brain. Acute parenchymal haemorrhage in the right frontal lobe, genu and proximal body of corpus callosum having intra-ventricular extension into all ventricles with resultant hydrocephalus and 4th ventricular extension causing compression of the brain stem.

[Table/Fig-4]: MRI brain. Shows irregular enhancing lesion involving right globus pallidus and internal capsule.

Maternal profile	Number (%) n=54
Age (years) [mean±SD]	29.26±3.22* (years)
Parity	
• Primigravida	40 (74)
• Multi	14 (26)
Co-morbidity	
• Hypertension	12 (22)
• Diabetes	2 (3.7)

[Table/Fig-6]: Maternal profile.

Symptom	Number n=54*(%)
Seizure	34 (62.9)
Headache/Visual disturbances	8 (14.8)
Paresthesias	5 (9)
Loss of consciousness	4 (7.4)
Hemiparesis/Quadriplegia	2 (3.7)
Speech disturbances	2 (3.7)
Ataxia	2 (3.7)

[Table/Fig-7]: Clinical manifestations.

*Number does not correlate as the same patient presented with more than one symptom.

RESULTS

Fifty four women with neurological manifestations in pregnancy were studied. The mean age was 29.26±3.22 years, with majority of women being primigravida (74%). Hypertension was the most common co-morbidity in the present study (22%) [Table/Fig-6].

Irrespective of the spectrum of neurological disorders seizure was the most common manifestation (63%), next being headache [Table/Fig-7].

Neurological manifestation	Number n (%)	Pregnancy outcome
Related to pregnancy	22 (40.8)	
Eclampsia	22 (40.8)	Live born - 18 Abortion - 1 IUD* - 1 FGR** - 16
Pre-existing neurological disorder	20 (37)	
Epilepsy	20 (37)	Live born - 19 Abortion - 1 FGR** - 7
Incidental causes	12 (22.2)	
Infection/Inflammatory	8 (66.66)	
• Tubercular meningitis	4	2 - Live born, 2 - Abortion
• Carpel tunnel syndrome	1	Live born
• Multiple sclerosis	1	Live born
• Guillain Barre syndrome	1	Live born
• Disseminated toxoplasmosis	1	Abortion
Structural Malformation	3 (25)	
• Spinal arterio-venous malformation	1	MTP#
• Mesial temporal sclerosis	1	Live born
• Cerebral cavernoma	1	NND\$
Others	1 (8.33)	
• Bartter syndrome	1 (8.3)	Live born

[Table/Fig-8]: Spectrum of neurological disorders and pregnancy outcome.
* = IUD: Intrauterine fetal Demise, ** = Fetal growth restriction, # = MTP: Medical Termination of Pregnancy, \$ = NND: Neonatal Death.

[Table/Fig-8] shows the spectrum of neurological disorders divided as related to pregnancy (40.8%), pre-existing neurological disorders (37%) and as incidental causes (22.2%), along with the pregnancy outcome. Sixty-five percent of the patients with epilepsy had good seizure control on monotherapy, however 7(35%) patients had seizure during pregnancy requiring additional anti-epileptic medication. There was 1 patient with status epilepticus who was managed by intravenous levetiracetam and recovered without any neurological sequelae. Folic acid supplementation was continued all through the pregnancy and there was no congenital malformation or haemorrhagic disease of the new born in the present study. The patients with epilepsy had a better perinatal outcome compared to eclampsia. Though the live birth rates in epilepsy (85%) and eclampsia (81%) were comparable, the perinatal morbidity due to Fetal Growth Restriction (FGR) was clearly more in eclampsia (72.7%) in comparison to epilepsy (35%). There were 3 Intrauterine Deaths (IUD) in eclampsia on arrival itself, whereas there was no perinatal mortality in patients with epilepsy.

Four out of 8 patients with neurological manifestations, due to infection or inflammatory aetiology were secondary to tubercular meningitis. 2 patients with tubercular meningitis were diagnosed and treated in first trimester and hence resulted in uneventful pregnancy. Another two patients had spontaneous abortion because of late referral and delay in diagnosis and treatment.

There was 1 patient with carpal tunnel syndrome who had uneventful pregnancy and the condition improved in the postnatal period without any intervention.

Another patient presented at 32 weeks of gestation with paresthesias, not responsive to neurotonics, folate and vitamin B12 supplementation. Sural nerve biopsy showed features suggestive of acquired inflammatory neuropathy. MRI brain confirmed the findings of multiple sclerosis. She improved symptomatically with steroid therapy and had good pregnancy outcome resulting in a live born baby.

There was a second gravida who presented at 17 weeks of gestation with severe throbbing headache and photophobia. Neuroimaging (MRI) confirmed the diagnosis of mesial temporal

sclerosis which manifests as temporal lobe epilepsy. She was started on ant-epileptic medication, pregnancy continued and resulted in a live birth.

A patient presented at term gestation with progressive ascending muscle weakness preceded by gastroenteritis. Neurological examination and nerve conduction studies confirmed the diagnosis of Guillain Barre Syndrome (GBS). She delivered a live female baby by elective cesarean section. Postnatally she was started on intravenous immunoglobulins and showed a gradual improvement.

DISCUSSION

The most common neurological disorder seen during pregnancy is epilepsy the incidence being 3-5 per 1000 births [1,2]. Pharmacokinetics of various antiepileptic drugs are altered as a result of increased renal blood flow and increased glomerular filtration and increased renal clearance. Similarly altered liver metabolism resulting in increased glucuronidation reduces the availability of the drug which may precipitate seizures. Safety of antiepileptic drugs in the first trimester of pregnancy should be considered [3]. Hence the knowledge of pre-existing disorders requires special consideration before, during and after pregnancy. A seizure free interval of 9 months prior to pregnancy prevents recurrence during pregnancy [4]. Recurrent convulsions in an epileptic patient during pregnancy require estimation of drug levels. Seizure in a patient without epilepsy requires determination of serum electrolytes, calcium and glucose levels.

Hypertensive disorders in pregnancy accounts for 12% of maternal mortality worldwide [5]. The eclamptic seizures are unique to pregnancy. Hence treatment of severe hypertension in pregnancy and prompt administration of magnesium sulphate will certainly aid in prevention of eclampsia and its associated complications.

Pregnancy is a hypercoagulable state with increased production of prothrombotic factors and fibrinogen levels and relative deficient fibrinolytic activity predisposes to vascular thrombotic events like Cerebral Venous Thrombosis (CVT) which can be life threatening if there is delay in diagnosis and management [6].

Infections like tuberculosis, toxoplasmosis may manifest with disseminated infection causing cerebral involvement and neurological manifestations as seen in our series. This increased susceptibility is believed to be due to immunological changes that occur during pregnancy. Tuberculosis and toxoplasmosis should always be considered in differential diagnosis of infectious aetiology involving multiple organs in pregnancy [7].

Pregnancy may be the first time to diagnose otherwise asymptomatic Arterio-Venous (AV) malformations. These vascular anastomosis are known to increase secondary to hormonal influence thereby making the patient symptomatic. These AV malformations can rupture leading to torrential haemorrhage and stroke. If unruptured, it can cause compression on the nerve roots resulting in neurological deficits [8,9]. Hence, if AV malformations are detected, correction (embolization of feeding vessel or surgical clipping) prior to pregnancy or soon after delivery is recommended to prevent the complications. The patient in our series improved soon after termination of pregnancy as the precipitating pregnancy changes reverted.

Risk of intracranial haemorrhage increases in pregnancy due to changes like increase in cardiac output, blood volume, vasodilatation and other hormone related changes. Symptomatic cerebral cavernomas can lead to massive intraventricular haemorrhage. If diagnosed prior to pregnancy or during pregnancy a corrective neurosurgery improves the pregnancy outcome. However it may be a catastrophe in the event of massive intracranial bleed with atypical presentation making the diagnosis uncertain, as in our patient (case 2) [10]. Intracranial haemorrhage generally has poor

prognosis in pregnancy. If a patient is admitted in a comatose state it is important to look for focal deficits and signs of meningeal irritation.

Multiple sclerosis usually has remission during pregnancy due to protective influence of high estrogen levels suppressing immune mediated disease activity. Relapse is likely to occur in postpartum period. Among the drugs used for disease modifying therapy, glatiramer acetate Food and Drug Administrative (FDA Category B) is considered safe in pregnancy [11].

Carpal tunnel syndrome is due to fluid retention and the physiological changes in the musculoskeletal system in pregnancy. Wrist splints may help to relieve the symptoms. It usually resolves in the postpartum period [12].

There are non-neurological conditions which can manifest with neurological symptoms like altered sensorium or coma due to dyselektrolytemia. Hence imaging plays a very vital role not only in making the diagnosis of a primary neurological condition, but also to exclude the central cause in case imaging is normal as was evident in the above mentioned case 5. Bartter syndrome is an autosomal recessive disorder secondary to gene mutation. It results in the impairment of sodium chloride transport across loop of henle and distal convoluted tubule. The metabolic abnormalities in this syndrome are hypokalemia, hypomagnesemia, metabolic alkalosis, hyperreninemia and hyperaldosteronism. Treatment aims at minimizing the effects of secondary increase in prostaglandins and renin aldosterone production and also correction of volume deficit by adequate hydration and correction of electrolyte imbalance by lifelong potassium supplementation as well as administration of potassium sparing diuretic [13].

Guillain Barre syndrome is another rare autoimmune neurological disease more often seen in postpartum period due to increase in proinflammatory cytokines. The disease characterized by acute inflammatory polyneuropathy with ascending progressive weakness of legs is usually preceded by infections. Respiratory complications are common in third trimester and risk of maternal mortality is high [14].

In the present study, we found that women with pre-existing neurological disorders had a better pregnancy outcome because of anticipation of complications and multi-disciplinary approach. The maternal outcome in women with eclampsia was good due to administration of magnesium sulphate. The role of neuroimaging was reemphasized in the present study. Imaging not only led to the diagnosis of an unusual case of disseminated toxoplasmosis but also ruled out primary neurological disease in a patient who presented in comatose state, who on further evaluation was found to have resistant hypokalemia (suspected Bartter syndrome). The present study also shows that, though tuberculosis is the commonest infection in our country, it can have varied manifestations causing a diagnostic dilemma. Hence a high index of suspicion is necessary to establish a diagnosis.

LIMITATION

The main limitation of this study is that the study period was limited to one year, extending the duration of study perhaps would have thrown more light. The post delivery follow-up was limited to 2

months which is the routine postnatal visit even though patients were asked to visit neurology department for further care.

CONCLUSION

Acute neurological symptoms in pregnancy warrant an urgent neurological review. A wide index of suspicion is required to make a diagnosis in pregnancy as the neurological manifestation during pregnancy may be highly varied due to hormonal influences and also the exaggerated physiological responses during pregnancy. Neurological manifestation during pregnancy may not always be a primary neurological disorder, instead may be manifestation secondary to any systemic illness. Multi-disciplinary approach before, during and after pregnancy is recommended for a better pregnancy outcome. Obstetric management has to be individualized as in those with increased intracranial pressure, cesarean delivery may be safer. Neuroimaging is both a diagnostic and complimentary tool in management of neurological disorders in pregnancy. New onset seizures in a non-epileptic, normotensive woman can have adverse maternal and perinatal outcome, hence early intervention is recommended. Coma may not always be a manifestation of primary neurological disease. Prompt diagnosis and treatment has a better outcome.

ACKNOWLEDGEMENTS

We express our sincere thanks to the physicians, neurophysicians, neurosurgeons and radiologists of Kasturba Medical College (KMC) Manipal who helped us in the management of patients.

REFERENCES

- [1] Haider B, Oertzen JV. Neurological disorders. *Best practice & Research Clinical Obstetrics and Gynaecology*. 2003;27:867-75.
- [2] Harden CL, Meador KJ, Pennell PB, Hauser WA, Gronseth GS, French JA, et al. Practice parameter update: management issues for women with epilepsy—focus on pregnancy: teratogenesis and perinatal outcomes: report of the quality standards subcommittee and therapeutics and Technology Assessment Subcommittee of the American academy of neurology and america epilepsy Society. *Neurology*. 2009;73(2):133-41.
- [3] Chang J, Streitman D. Physiologic adaptations to pregnancy. *Neurol Clin*. 2012;30:781-89.
- [4] Harden CL, Hopp J, Ting TY, Pennell PB, French JA, Hauser WA, et al. Practice Parameter update: Management issues for women with epilepsy—Focus on pregnancy (an evidence-based review): Obstetrical complications and change in seizure frequency. *Neurology*. 2009;73(2):126-32.
- [5] Mustafa R, Ahmed S, Gupta A, Venuto RC. A comprehensive review of hypertension in pregnancy. *Journal of Pregnancy*. 2012;2012.
- [6] James AH. Venous thromboembolism in pregnancy. *Arterioscler Thromb Vasc Biol*. 2009;29(3):326-31.
- [7] Paruthikunnan S, Shankar B, Kadavigere R, Prabhu M, Narayanan R, Jain H. An unusual case of disseminated toxoplasmosis in a previously healthy pregnant patient: radiographic, CT, and MRI findings. *Jpn J Radiol*. 2014; 32:664-69.
- [8] Ghulmiyyah L, Sibai B. Maternal mortality from preeclampsia/eclampsia. *Semin Perinatol*. 2012;36:56-59.
- [9] Hart LA, Sibai BM. Seizures in pregnancy: Epilepsy, eclampsia, and stroke. *Semin Perinatol*. 2013;37:207-24.
- [10] Simonazzi G, Curti A, Rapacchia G, Gabrielli S, Pilu G et al. Symptomatic cerebral cavernomas in pregnancy: A series of 6 cases and review of the literature. *Matern Fetal Neonatal Med*. 2014;27(3):261-64.
- [11] Buraga I, Popovici RE. Multiple Sclerosis and Pregnancy: Current considerations. *The Scientific World Journal*. 2014;2014.
- [12] Osterman M, Ilyas AM, Matzon JL. Carpel tunnel syndrome in pregnancy. *Orthop Clin North Am*. 2012;43(4):515-20.
- [13] Bhat YR, Vinayaka G, Sreelakshmi K. Antenatal Bartter Syndrome: A Review. *International Journal of Pediatrics*. 2012;2012.
- [14] Meenakshi-Sundaram S, Swaminathan K, Karthik SN, Bharathi S. Relapsing Guillain-Barre syndrome in pregnancy and postpartum. *Ann Indian Acad Neurol*. 2014;17:352-54.

PARTICULARS OF CONTRIBUTORS:

1. Senior Resident, Department of Obstetrics and Gynaecology, St John's Medical College, Bangalore, India.
2. Professor and Head of Department, Department of Obstetrics and Gynaecology, Kasturba Medical College, Manipal, Udupi, India.

NAME, ADDRESS, E-MAIL ID OF THE CORRESPONDING AUTHOR:

Dr. Lavanya Rai,
Professor and HOD, Department of Obstetrics and Gynaecology, Kasturba Medical College,
P.O. Box No. 7, Manipal – 576104, India.
E-mail: lavanya.raimanipal.edu, drsamskruthii@gmail.com

FINANCIAL OR OTHER COMPETING INTERESTS: None.

Date of Submission: **Feb 27, 2016**

Date of Peer Review: **Jun 03, 2016**

Date of Acceptance: **Sep 06, 2016**

Date of Publishing: **Dec 01, 2016**